



Clinical Cases Collection



Content

- ESRD 1**
 - 1.Combined Artificial Kidney Therapy Relieving Hypertension 1
 - 2.Combined Artificial Kidney Therapy Relieving Itching And Restless Legs Syndrome 2
- Drug Overdose 3**
 - 3.Hemoperfusion for Valproate Sodium Overdose 3
 - 4.Hemoperfusion for Benzodiazepine Toxicity 3
 - 5.High-volume Continuous Venovenous Hemodiafiltration Plus Resin Hemoperfusion
 - 6.Severe Suicidal Digoxin Toxicity Managed with Resin Hemoperfusion 4
 - 7.Severe Suicidal Digoxin Toxicity Managed with Resin Hemoperfusion 5
 - 8.Hemoperfusion for Unknown Drug Overdose 6
 - 9.Acute Renal Failure Induced by Rhabdomyolysis for Cocaine Abuse treated with HF+HP 7
- Autoimmune Disease 8**
 - 10.HA280 Used for Psoriasis Vulgaris 8
 - 11.Hemoperfusion for 4-year-old Child with Dermatomyositis 9
 - 12.Hemoperfusion for Autoimmune Hepatitis 10
- Critical Disease 11**
 - 13.Hemoperfusion for Polysegmentary Bilateral Pneumonia 11
 - 14.Case Report of Sepsis with Multi-organ Failure..... 12
 - 15.A Case Report of Septic Shock 13
- Liver Failure 14**
 - 16.Hemoadsorption for Hyperbilirubinemia & Encephalopathy 14
 - 17.A Case Report of DPMAS for Liver Failure 15
 - 18.Hepatitis A Virus-induced Severe Hemolysis Complicated by Severe Glucose-6-Phosphate Dehydrogenase Deficiency 16



Combined Artificial Kidney Therapy Relieving Hypertension

Sau Seng Lum Haemodialysis Center, Malaysia

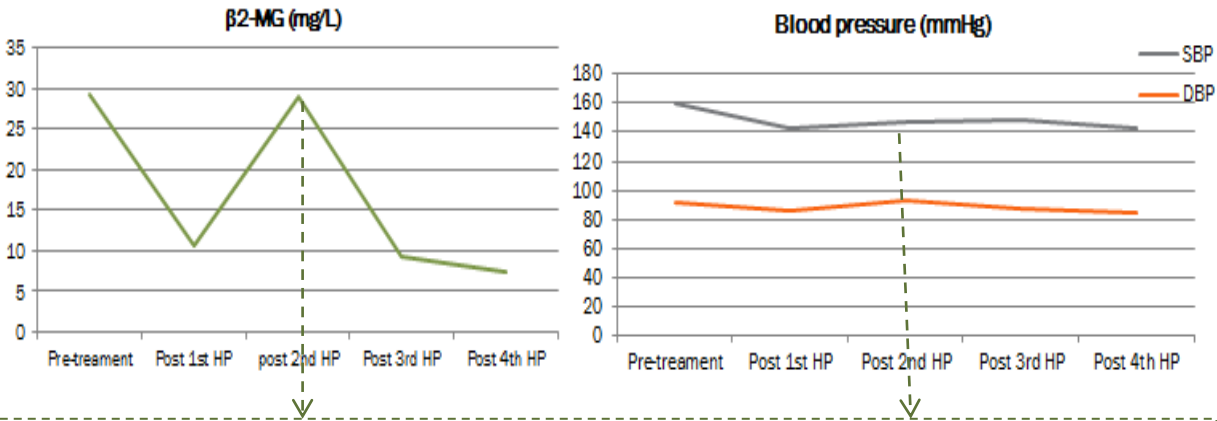
Introduction: This is a uremia with hypertension patient, associated with poor sleep and appetite at times. He is 45 years old with a dialysis history of 9 years. Along with the time, he received complications of MHD, but three times per week HDF treatment did not relieved the symptoms. His β 2-MG accumulated to 29.16 mg/L and blood pressure rise to 160/91.

Treatment: HP treatment is conducted once a week on March, twice a month on April and once a month from May on. HFHD is conducted 3 times a week.

Result :

Date	β 2-MG (mg/L)		Blood pressure	
	Pre	Post	Pre	Post
2016-03-24	29.16	10.63	160/91	143/86
2016-04-21	32.78	28.96	176/91	147/93
2016-05-12	28.51	9.21	164/98	148/88
2016-06-16	27.42	7.55	165/90	143/84

During three months HP treatment, his β 2-MG and blood pressure were under control and decreased gradually, and he regained better appetite and sleep.



After the first HP treatment, there is a slight rise of β 2-MG and blood pressure. It possibly because the patient's body is not adopted to the sharp reduce of the particular uremic toxins. So there might be feedback reactions that result in the slight jump when initiate HP treatment. With the continuing of the HP treatment, the value of the uremic toxins will finally come down and under control.

Conclusion: The combined artificial kidney (HD+HP) treatment can relieve the hypertension and decrease the β 2-MG for ESRD patients. It is a long term process to improve the patients' life quality step by step.



Combined Artificial Kidney Therapy Relieving Itching And Restless Legs Syndrome

The people's Hospital of Wuhan University (Hanchuan), China

Introduction :

This patient is 39 years old and developed uremia due to nephritis. After conventional HD for 9 years, he began to develop the complications such as itching and restless legs, associating with severe accumulation of PTH.

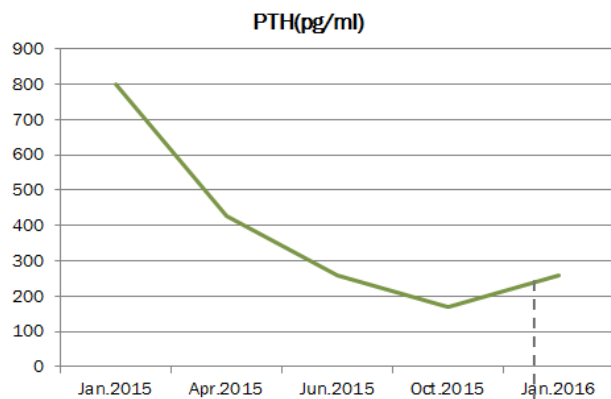
Treatment :

HD 3 times per week, HP twice a month, 120-150min each HP, until November 2015. Due to the Spring Festival, change HP into HDF for 1 month.

Result :

PTH significantly decreased gradually, symptom of itching and restless legs disappeared. PTH appeared a slight rise when change HP in to HDF for a month.

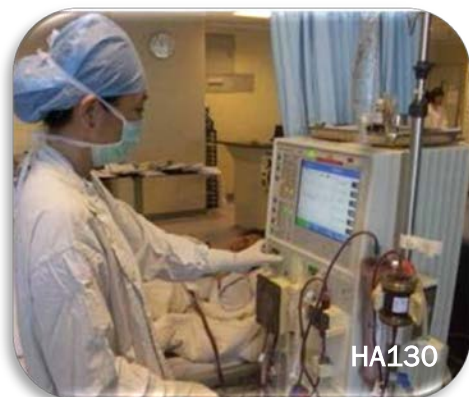Date	PTH(pg/ml)
2015-01-23	800.3
2015-04-25	427.4
2015-07-28	259.8
2015-10-21	169.3
2016-01-07	257.5



When change HP into HDF for 1 month, PTH rose again to 257.5pg/ml.

Conclusion:

This case suggested that combined artificial kidney (HP+HD) is helpful in removal of PTH. A maintenance treatment of HD+HP twice a month is efficacy in keeping a low concentration of PTH, relieving the symptom of itching and restless legs, improving patient's life quality.





Hemoperfusion for Valproate Sodium Overdose

Dr. Mitra Rahimi, Loghman-Hakim Hospital, Iran

Introduction: A 62-years-old female was loss of consciousness due to valproate sodium overdose and admitted to the hospital. As the patient did not response to all our supportive care & her level of consciousness did not change during 42 hours of admission. So she was candidate for hemoperfusion process with HA230 cartridge, on 3rd day of hospitalization.

Treatment:

HA230 direct hemoperfusion was done for 2.5 hours.

Blood flow rate: 200ml/min

Anticoagulation: heparin

Result :

Date	Clinical Change
4-5 hours post HP on 3 rd day	She gradually got better level of consciousness.
7 th day	The fever was resolved.
8 th day	she was extubated and then transferred to medical ward.
10 th day	She was discharged

Hemoperfusion for Benzodiazepine Toxicity

Dr. Mitra Rahimi, Loghman-Hakim Hospital, Iran

Introduction: A 58 years old man got unknown pesticide toxicity and admitted to the hospital due to complained of general weakness, drowsiness, nausea & vomiting. On 4th day of hospitalization. Atropine dropped from 168 to 84 mg and pralidoxime drip were prescribed for him but no clinical improvement was detected during 3 days of treatment. So the patient had hemoperfusion with HA230 cartridge.

Treatment:

HA230 direct hemoperfusion was done for 2.5 hours.

Blood flow rate 200ml/min

Anticoagulation: heparin

Result:

The result was apparently hopeful, because the patient began to tolerate for tapering Atropine drip and level of consciousness gradually improved.



High-volume Continuous Venovenous Hemodiafiltration Plus Resin Hemoperfusion Improve Severe Metformin-associated Toxicity

Guangdong General Hospital, China

Introduction:

A 42-year-old female presented to casualty with a history of ingestion of 100 metformin tablets (500 mg) 5 hours before admission. She had developed nausea and recurrent vomiting 30 minutes after ingestion.

Treatment and Result:

Time	■ Treatment method ● Result
4hrs after admission	<p>Due to refractory metabolic acidosis</p> <ul style="list-style-type: none">■ high-volume CVVH for 24hrs● Metformin decreased but no significant improvement of clinical symptoms
28hrs after admission	<ul style="list-style-type: none">■ HP+CVVH for 3 hours● Metformin decreased 61.8%.● Patient's general condition was improved.
7days after admission	<ul style="list-style-type: none">● She was discharged

Conclusion:

our case data demonstrate that patients with metformin overdose should be treated with extracorporeal therapy. When combined with concomitant cardiovascular support and maintenance of blood glucose, extracorporeal therapy provides the possibility of a good outcome in patients with metformin overdose. Combination of CVVH and hemoperfusion eliminated more metformin and metabolic products, and improved arterial blood pressure, hypoglycemia and lactic acid in metformin overdose.

DOI: 10.1111/jdi.12757



Severe Suicidal Digoxin Toxicity Managed with Resin Hemoperfusion

Max Super Speciality Hospital, New Delhi, India

Introduction:

A young female who presented to casualty with alleged history of consumption of 17.5 mg of digoxin tablets. After admission to ICU, she developed atrioventricular blocks with hemodynamic instability.

Treatment:

Due to

- High serum digoxin levels
- Bradyarrhythmias with hypotension
- No availability of Fab fragments

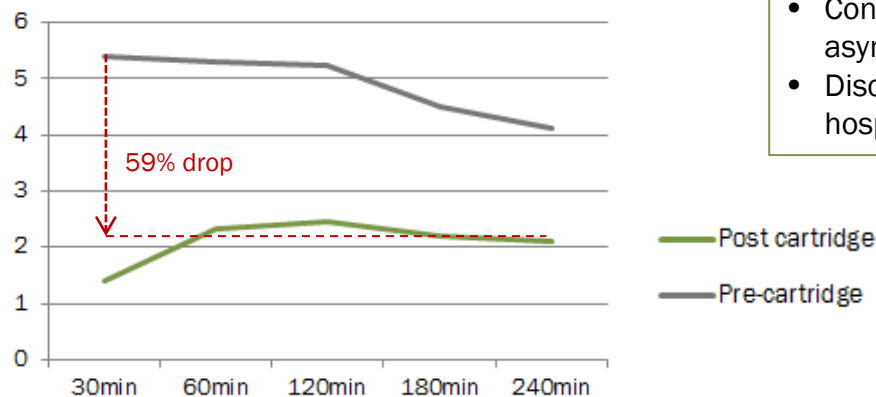


The patient received hemoperfusion treatment for over 4 hours.

Result:

Serum digoxin levels during resin hemoperfusion(ng/ml)

Time(min)	30	60	120	180	240
Pre-cartridge	5.41	5.31	5.23	4.50	4.12
Post cartridge	1.39	2.32	2.46	2.20	2.12



Patient's recovery

- Gradual symptomatic improvement
- Heart rate also improved
- Atrioventricular block got corrected over the next 24 h.
- Continue to remain asymptomatic
- Discharged after 4 days of hospitalization

Conclusion:

Resin hemoperfusion has been shown to be useful in managing patients with various intoxications including tricyclic antidepressant, chloral hydrate, and mushroom poisoning. Resin hemoperfusion may be tried for drugs like digoxin, which have a high lipid solubility. Hence, resin hemofiltration may be successfully and safely used as an alternative therapy, in conjunction with other supportive measures, to manage patients with digoxin toxicity especially when Fab fragments are unavailable.



Hemoperfusion for Unknown Drug Overdose

Dr. Mitra Rahimi, Loghman-Hakim Hospital, Iran

Introduction:

A 35 years old man loss of consciousness due to unknown toxicity and admitted to the hospital. Since his phenobarbital level reported 52 mg/d, so he underwent supportive care, but condition was unchanged. On the 2nd day, he had hemodialysis for 4 hours. But on the 3rd day of ICU Admission the phenobarbital raised to 77mg/dl, so toxicologic team decided to do hemoperfusion with HA230 cartridge.

Treatment:

HA230 direct hemoperfusion was done for 2 times, 2.5 hours each time.

Blood flow rate 200ml/min

Anticoagulation: heparin

Result :

The level of consciousness began to improve after second hemoperfusion but at that time ventilator associated pneumonia (VAP) happened. So he was not eligible for extubation & with klebsiella pneumonia in tracheal culture, antibiotic therapy was prescribed and at last we could extubate him on 11th day of hospitalization.

On 14th day of admission, he was transferred to ward.

On 15th day of his Entrance, his right leg apparently was asymmetrical, so a color doppler sonography was done for him which revealed thrombosis in CFU & partial thrombosis in proximal of SFU vein.

The treatment began & by internal medicine service & on 19th day of hospitalization, rivaroxaban was started with doses of 15 mg twice times a day for 21 days and advisements to follow up visit in clinics.



Acute Renal Failure Induced by Rhabdomyolysis for Cocaine Abuse treated with HF+HP

Pisa University, Italy

Introduction:

A 36 years old men with positive anamnesis for drugs abuse access the Emergency Room as a result of falling from the scooter complaining about myalgia and abdominal pain. After positioning urinary catheter we have seen production of urine very dark and toxicologic analysis evidence cocaine positivity.

Treatment & Result

T: 7 HF treatments were conducted at daily frequency for 4 hours

R: There was no improvements on renal functionality index, diuresis recovery, nor myoglobin decrease.

T: To improve removal efficiency of medium size molecular weight substances like myoglobin (17,8 kDa), the patient got 5 treatments of 6 - 8 hours HF combined with hemoperfusion treatment (HA330-II).

R: It showed a significant reduction of myoglobin levels and a gradual diuresis recovery.

T: The patients got 2 more treatments without the cartridge

R: After a drastic reduction of myoglobin levels and diuresis recovered, the patient has been discharged from the hospital.

Index	Urea	Creatinine	AST	ALT	LDH	CPK	Myohemoglobin
Pre-treatment	86 mg/dl	3.55 mg/dl	1221 U/L	236 U/L	2670 U/L	103.566 U/L	>30000 U/L
Discharge after 23 days	155 mg/dl	1.9 mg/dl					140 ng/ml
Last check after 2 months	86 mg/dl	0.99 mg/dl					Normal

Discussion:

This case shows the myoglobin effective removal associating intermittent HF with adsorbent mechanism (hemoperfusion). In our case after a 8 hours treatment with this method we have seen a significant myoglobin drop and a progressive reduction of their level in following treatments.



HA280 Used for Psoriasis Vulgaris

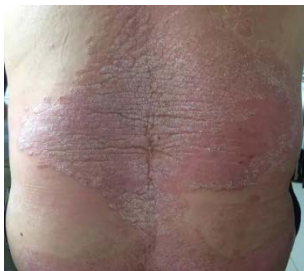Jianing Hospital, Anhui, China

Introduction:

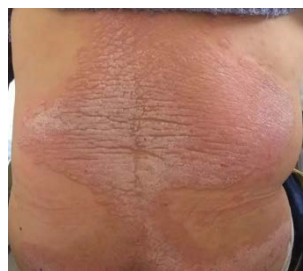A 67-year-old male, suffering from polyuria and polydipsia for over 10 years, was admitted to hospital due to poor glucose control for half a month. He was diagnosed with Psoriasis Vulgaris (erythematous type).

Treatment & Result

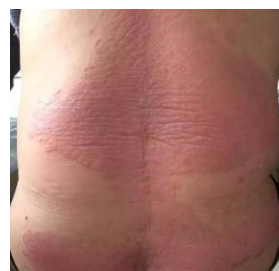Date	HA280 hemoperfusion treatment based on conventional medical treatment	Result
March 20	HP for 2hrs	No obvious change
March 22	HP for 2hrs	Skin itching was relived
March 25	HP for 2hrs	Damaged skins of back began to scab.
March 29— April 3	2hrs HP conducted every other day	No adverse reactions; The patient felt better with healing skin.
April 5— April 15	2hrs HP conducted every three days	This was no significant difference of the normal skin and his back skin.



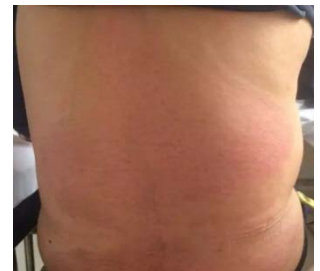Pre-treatment



Post 3rd HP treatment



Post 5th HP treatment



Post 10th HP treatment

Discussion:

Hemoperfusion treatment can adsorb large molecular substances and pathogenic factors mainly including cytokines and immune mediators such as β 2MG, leptin, IL-1, IL-6, IL-8, TNF-a, etc. Meanwhile, it can clear the soluble immune complex and some antibodies. Commonly, hemoperfusion treatment should be combined with medicine therapy and other kind of clinical method to achieve better efficacy.

Hemoperfusion for 4-year-old child with Dermatomyositis

Guangzhou Women and Children's Medical Center, Guangdong, China

Introduction:

This is a 4-year-old boy (17kg) diagnosed with dermatomyositis and bronchopneumonia. He suffered from rash, dysphagia, cough, etc. for over 20 days.

Treatment:

- Single HA280 hemoperfusion treatment for 2hrs
- Observe APTT every 30min and adjust the heparin dosage
- Give protamine to neutralize the heparin when return blood
- The day after HP treatment, continue with methylprednisolone 5mg/kg by intravenous drip

Result:

Table 1 Blood WBC, PLT, CRP changes before and after adsorption treatment

	WBC($\times 10^9/L$)	PLT($\times 10^9/L$)	CRP (mg/L)	
Pre-HP	19.5 \pm 4	6196 \pm 51	3.3 \pm 1.9*	*= P <0.05
Post HP	15.7 \pm 2.3	235 \pm 51	0.5 \pm 0*	

Table 2 Blood enzymology changes before and after adsorption treatment

	ALT (U/L)	AST (U/L)	LDH (U/L)	CK (U/L)	CK-MB (U/L)	TG (mmol/L)	Globulin (g/L)	Albumin (g/L)
Pre-HP	51.0 \pm 29.0	127* \pm 39	593.0 \pm 121.0	848 \pm 677	40.0 \pm 6.2	4.65 \pm 4.3	41.4 \pm 11.2	38.0 \pm 1.10
Post-HP	25.0 \pm 1.5	66.0* \pm 11.0	471.0 \pm 54.0	237 \pm 56	33.0 \pm 6.6	1.72 \pm 1.1	32.4 \pm 3.00	34.7 \pm 4.60

Table 3 Immune index changes before and after adsorption treatment

	IgG (g/L)	IgM (g/L)	IgA (g/L)	C ₃ (g/L)	C ₄ (g/L)	ANA
Pre-HP	18.7 \pm 1.1	1.30 \pm 0.18	1.64 \pm 0.26	1.00 \pm 0.13	0.18 \pm 0.02	+
Post-HP	14.2 \pm 1.8	1.00 \pm 0.02	1.22 \pm 0.04	0.76 \pm 0.19	0.17 \pm 0.03	-



After hemoperfusion treatment, clinical symptoms has been obviously improved. The patient became more sensitive to cortin and his ANA became negative. CRP had a significant decrease ($P < 0.05$) and the immune index including IgA, IgM, C_3 , C_4 reduced after the hemoperfusion treatment.

Discussion:

Compared to plasma exchange, HA280 hemoperfusion treatment is easy to operate and doesn't affect other medicine treatment. Notably, as hemoperfusion is an extracorporeal circulation, emphasized monitoring management should be conducted especially to kids. At the beginning of hemoperfusion treatment, the patient showed early hemorrhagic shock and he recovered after the supplement of blood products.

Hemoperfusion treatment can help patients go through the critical stage and immune storm in a short time and make patients more sensitive to medicine treatment, in which case the medicine efficacy will be improved and the treatment time will be shortened.

DOI: 10. 3760 / cma.j.issn.2095-428X.2014.09.008

Hemoperfusion for Autoimmune Hepatitis

Clinical hospital N 2, Moscow, Russia

Introduction:

Patient: women, 54 years. Weight: 130 kg. At the time of admission, 43 days is sick.
Diagnosis: autoimmune hepatitis

Treatment:

With the attempt to stop the autoimmune process, the patient received HA280 hemoperfusion treatment.

Preparing of the column:

500 ml of 5% glucose, 5 bottles with 500 saline with the addition of 1000 units of heparin in each bottle. A speed of washing - 100 ml / min, a lot of air leaved the column.

Anticoagulation during procedure:

sodium citrate 1/18 - 1/25. The volume of procedure is 10 liters. Without problems. The air did not come out of the column, the level in the air trap did not fall. The blood speed is 100-150 ml / min.

Result:

Positive effect. Stabilization of ALT and AST. Autoimmune process decreased.



Hemoperfusion for Polysegmentary Bilateral Pneumonia

Clinical hospital N 1 (Volynskaya), Moscow, Russia

Introduction:

A 90 years old female who weighs 80kg was diagnosed with Polysegmentary bilateral pneumonia. The patient's condition is regarded as septic - unstable hemodynamics and vasopressors are prescribed in a dose of 0.6 per 1 minute. His procalcitonin is 88, leukocytes is 54400.

Treatment:

The procedure of hemoperfusion using the HA 330 column. Column was prepared in accordance with the instructions. Heparin was injected in the dose 25,000 units. Total heparinization was 5000 units per procedure. The blood flow rate was 100 ml/ min. The total volume of perfusion was 30 liters of blood.

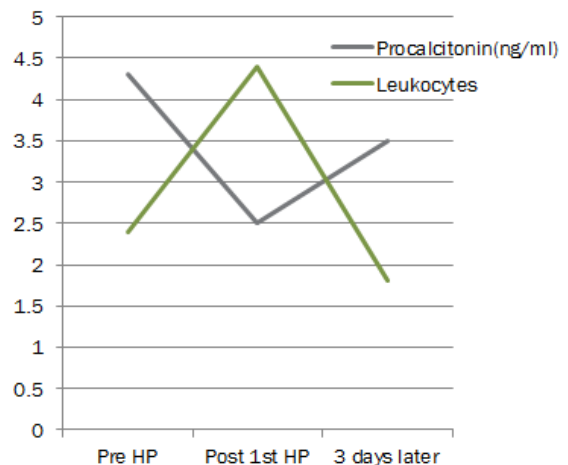
Results:

The procedure went smoothly without hemodynamic disorders from the patient and the device.

The next day procalcitonin was 46, leukocytes is 37000. Norepinephrine is reduced up to 0.3/min.

Three days after the procedure: procalcitonin was 2.5, leukocytes is 7000, vasopressors canceled.

Indicator	Procalcitonin (ng/ml)	Leukocytes
Pre HP	88	54400
Post 1st HP	46	37000
3 days later	2.5	7000



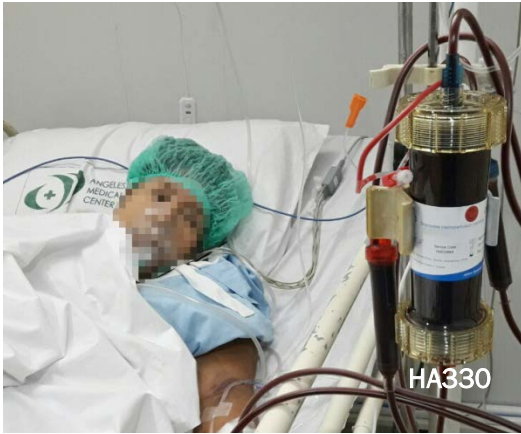Conclusion:

The patient showed positive dynamic after hemoperfusion treatment. He did not develop organ failure and recover in consciousness. His kidney function was preserved and was not transferred to artificial ventilation.



Case Report of Sepsis with Multi-organ Failure

Anges Medical Center, Philippines



A patient admitted to the hospital due to fever associated with jaundice and vague abdominal pain and was worked up and managed as cholangitis secondary to common bile duct stone.

Due to sudden onset of dyspnea she was transferred to the ICU and referred to the multi-specialty team due to multi-organ dysfunction due to severe septicemia with beginning DIC.

On 2nd ICU day, the patient developed oliguria associated with progressive azotemia and acidemia hence he received a combination of HD+HP. Her creatinine level was 4.48mg/dL and procalcitonin was 27.28ng/mL

24h later, the patient is cleared to undergo ERCP.

Due to persistence of oliguria and azotemia, another session of HD was done

36 hours post HD+HP procalcitonin was 10.62 ng/mL which was associated with improvement of hemodynamic stability.

On 5th ICU day, renal function was markedly improved (creatinine 1.67 mg/dl), noted to have adequate urine output and was cleared to transfer to wards.

Indicator	Pre-treatment	Post-treatment
Creatinine (mg/dL)	4.48	1.67
Procalcitonin (ng/mL)	27.28	10.62

She was eventually discharged, improved and scheduled for either repeat ERCP vs surgery after 2 weeks.

Multi-specialty comments:

The use HD+HP offered a unique and novel approach to the management of multi-organ failure due to severe sepsis and is viewed in this case as an important intervention which not only showed improvement of sepsis parameters like procalcitonin but translated to hastened clinical recovery of many organs together with prompt intervention for primary cause of the disease.



A Case Report of Septic Shock

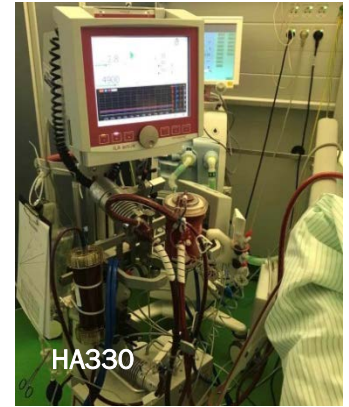Aachen University hospital, Germany

Introduction:

65-years-old male, septic shock with multi organ failure, transferred to Aachen Univ. Hospital ICU. He had ECMO, CVVH and 5 times resuscitation on the first day of admission, but the condition still out of control with extremely high inflammation indicators. So he start HA330 hemoperfusion at 17:00 on Sep. 18th.

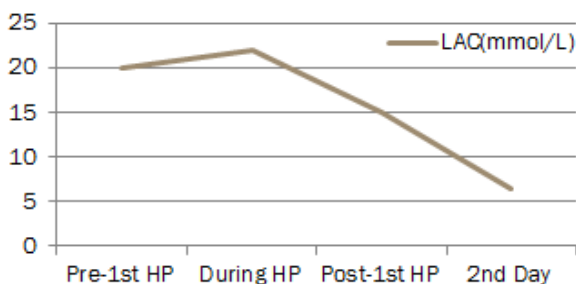
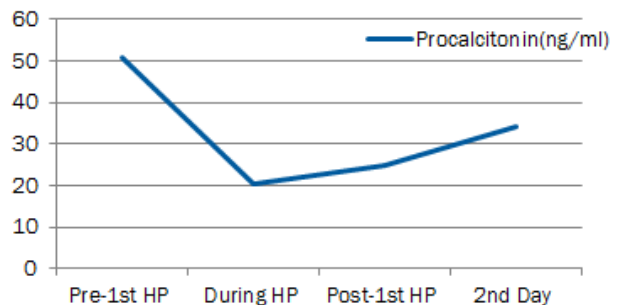
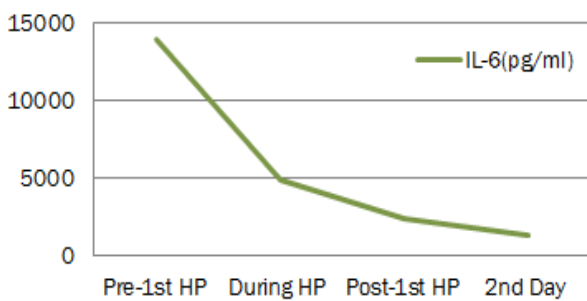
Treatment:

HP on ECMO, once a day



Result:

	Pre-1 st HP	During HP	Post-1 st HP	2 nd Day
IL-6(pg/ml)	13945	4937	2469	1387
Procalcitonin(ng/ml)	50.94	20.52	24.96	36.17
LAC(mmol/L)	20	22	15	6.5



The inflammatory indicators including IL-6, procalcitonin and lactate decreased obviously after once hemoperfusion treatment. However, the patients finally died of severe lung failure.

Comments: More earlier hemoperfusion treatment before the end point is needed to gain better survival opportunity.



Hemoadsorption for Hyperbilirubinemia & Encephalopathy

Clinical hospital N 2, Moscow, Russia

Introduction: A 64 years old female with weight of 76kg has been sick for 23 days at the time of admission. She was diagnosed with hyperbilirubinemia and encephalopathy.

Treatment:

Hemoadsorption using HA330-II.

Preparing of the column: 500 ml of 5% glucose, 5 bottles with 500 saline with the addition of 1000 units of heparin in each bottle. At speed of washing - 100 ml/min.

Anticoagulation during procedure:

Sodium citrate 1/18 - 1/25. The volume of procedure is 10 liters. Without problems. The air did not come out of the column, the level in the air trap did not fall. The blood speed is 100-150 ml / min.

Result:

Total bilirubin before: 439, after 387.

Conclusion:

Positive effect: The patient regained consciousness, is available to the contact. There is a marked decrease in encephalopathy.



A Case Report of DPMAS for Liver Failure

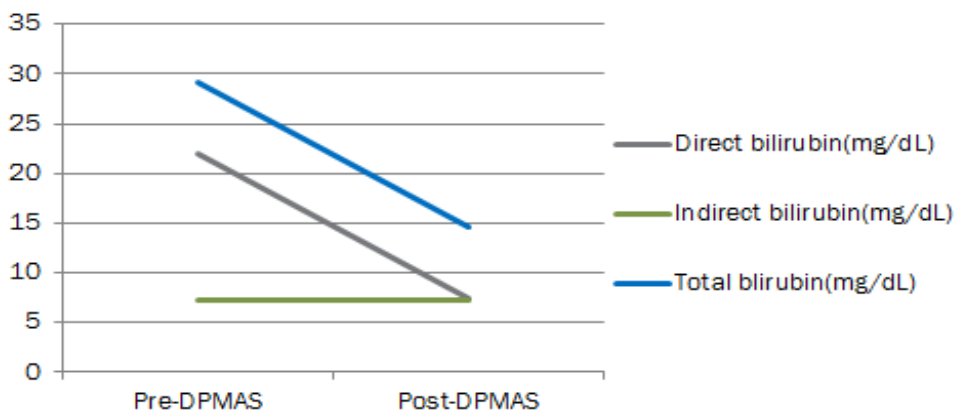
Frankfurt Cancer Center, Germany

Introduction:

A 63-years-old female with liver metastasis after breast cancer.

Treatment & Result:

Date	Treatment Result
19/12/2017	Chemotherapy
20/12/2017	HA330+HA230 hemoperfusion The patient felt much better regarding fatigue and vomit, and CRP reduced from 60.04mg/L to 21.27mg/L.
4/1/2018	HA330-II hemoperfusion due to tendency of acute liver failure and to maintain a good status. After treatment bilirubin reduce significantly and IL-6 decreased from 12,000+ to 5,000+pg/ml
9/1/2018	DPMAS again due to hyperbilirubinemia. After the treatment the bilirubin reduced sharply.



One week later she received another DPMAS treatment. After 2 times DPMAS treatment ,her liver function recovered and could received the chemotherapy continuously.



Hepatitis A Virus-induced Severe Hemolysis Complicated by Severe Glucose-6-Phosphate Dehydrogenase Deficiency

Max Super Speciality Hospital, New Delhi, India

Introduction:

A 39-year-old male, not previously diagnosed with G6PD deficiency, who presented with viral hepatitis, severe hemolysis and multiorgan failure.

Method:

In view of worsening sensorium, life-threatening multiorgan failure, and high bilirubin and ammonia levels, he received **DPMAS** (HA330-II+BS330) treatment on the first day and **HA330-II** adsorption treatment on the third day.

Result:

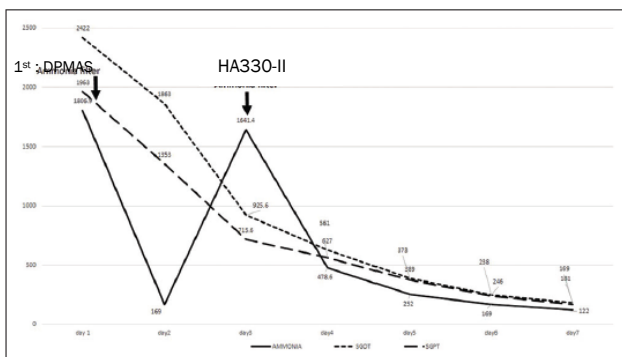


Figure 1: Serial ammonia, serum glutamic oxaloacetic transaminase, serum glutamic pyruvic transaminase levels, and effect of ammonia filters

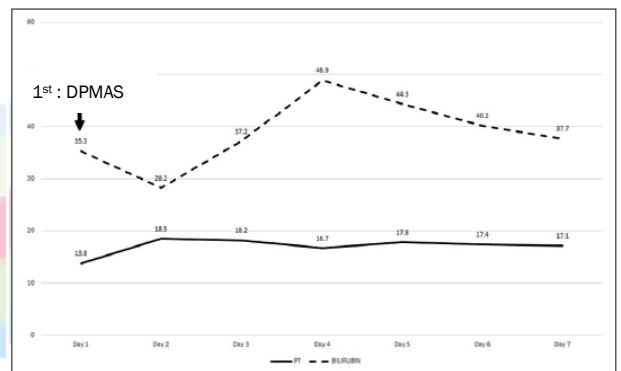


Figure 2: Serial bilirubin and prothrombin levels and effect of bilirubin filter

After 48h of aggressive management, the patient started to show clinical recovery with the improvement in sensorium, normalization of blood pressure, and reduced oxygen requirement. Combined with other treatment, he was shifted out of ICU after day 6 and was discharged from the hospital after 11 days of hospitalization.

Discussion:

Liver support system using hemoperfusion cartridge was applied in our case in view of severe hyperbilirubinemia, multiorgan failure, and worsening sensorium. Non-bioartificial liver support may be indicated in patients with acute liver failure as these may have good short-term efficacy and reduce the level of hepatic encephalopathy, reduce serum bilirubin levels, improve prothrombin activity or international normalized ratio, and may also improve other laboratory parameters, including blood ammonia and endotoxins. In our case too, it helped in reducing bilirubin and ammonia levels and tide over the acute crisis.